Protein measurement with the Folin phenol reagent. *Journal of Biological Chemistry* **193,** 265-275
MAUSS, S., CHAPONNIER, C., JUST, I., AKTORIES, K. & GABBIANI, G. (1990) ADP-ribosylation of actin isoforms by *C botulinum* C2 toxin and *C perfringens* iota toxin. *European Journal of Biochemistry* **194,** 237-241
MORRISHI, K. S. B., KUBO, S. & OGUMA, K. (1989) Molecular diversity of neurotoxins from *Clostridium botulinum* type D strains. *Infection and Immunity* **61,** 5309-5314
POXTON, I. R. (1984) Demonstration of the common antigens of *Clostridium botulinum, C sporogenes* and *C novyi* by an enzyme linked immunosorbent immunoassay and electroblot transfer. *Journal of General Microbiology* **130,** 975-981
SCHIAVO, G., SHONE, C. C., BENNETT, M. K., SCHELLER, R. H. & MONTECUCCO, C. (1995) Botulinum neurotoxin type C cleaves a single Lys-Ala bond within the carboxy-terminal region of syntaxins. *Journal of Biological Chemistry* **270,** 10566-15070
WHITWELL, K. (1991) Do hares suffer from grass sickness? *Veterinary Record* **128,** 395-396
WHITWELL, K. & NEEDHAM, J. (1996) Mucoid enteropathy in UK rabbits: dysautonomia confirmed. *Veterinary Record* **139,** 323-324

Stabilisation of scoliosis in two koi *(Cyprinus carpio)*

P. D. GOVETT, N. J. OLBY, D. J. MARCELLIN-LITTLE, D. S. ROTSTEIN, T. L. REYNOLDS, G. A. LEWBART

Two koi *(Cyprinus carpio)* from the same pond developed similar lesions of scoliosis. Radiographic examinations showed that their spines had become malaligned as a result of vertebral compression fractures involving T14 to T16. The vertebrae in both fish were stabilised with screws, k-wire and polymethylmethacrylate. They both appeared to improve after surgery, but they began to decline and died within three months. A postmortem examination revealed multi-organ inflammation that was not associated with the surgical implants.

Veterinary Record (2004) **155,** 115-119

P. D. Govett, DVM,
G. A. Lewbart, MS, VMD, DACZM,
Environmental Medicine Consortium and Department of Clinical Sciences,
N. J. Olby, VetMB, PhD, DACVIM,
D. J. Marcellin-Little, DEDV, DACVS, DECVS,
Department of Clinical Sciences,
D. S. Rotstein, DVM, MSPVM, DACVP,
T. L. Reynolds, DVM,
Department of Population Health and Pathobiology, College of Veterinary Medicine, North Carolina State University, 4700 Hillsborough Street, Raleigh, NC 27606, USA

Dr Rotstein's present address is Department of Pathobiology, University of Tennessee, College of Veterinary Medicine, 2407 River Drive, Knoxville, TN 37996, USA

SCOLIOSIS, or 'bent-back', in koi (*Cyprinus carpio*) is being reported more often. Many causes have been suggested, including vitamin C deficiency (John and others 1979, Halver and Hardy 1994); electrocution as a result of either lightning strike (Barlow 1993), faulty submersible pumps (Johnson 1997) or electrofishing (Sharber and Carothers 1988); tryptophan deficiency (Halver and Shanks 1960, Kloppel and Post 1975, Poston and Rumsey 1983, Walton and others 1984, Post 1993); trauma; organophosphates (Couch and others 1977, Alam and Maughan 1993, Waddington 1995); and bacterial cold water disease (Noga 1996). Although some fish continue to do well with a noticeable curvature of the spine, others become debilitated and intervention becomes necessary. This paper describes the progression of the condition and the surgical stabilisation of scoliosis in two koi.

CASE HISTORY 1

In July 2001, an approximately two-year-old, 56 cm, 1314 g, female doitsu sanke koi developed a 3 cm chevron-shaped ulcer, dorsal to its right pectoral fin. The fish shared a 56,775 litre pond, with a maximum depth of 137 cm, with 30 other koi and 10 goldfish (*Carassius auratus*). The water quality had been good, but in the previous three months some of the fish had developed ulcerative skin disease, and when this koi began separating itself from its school the ulcer was first noticed. The koi had been treated by the owner with a series of three injections of 5·7 mg/kg amikacin sulphate (Amiglyde-V, 50 mg/ml; Fort Dodge) administered intracoelomically every 48 hours. When the injections were given, the ulcer was cleansed with 10 per cent povidone-iodine solution (Betadine; Purdue Frederick) and then treated with a topical triple antibiotic ointment (Neosporin; Warner Lambert). All the fish in the pond were provided with paste food containing 0·5 mg/g enrofloxacin (Baytril 2·27 per cent; Bayer Corporation) at a dose of 10 mg enrofloxacin/kg/day. When there was no improvement, the paste food was instead impregnated with 2 mg/g trimethoprim-sulphadiazine (Tribrissen; Schering-Plough) and fed to provide a dose of 30 mg/kg/day, upon a veterinarian's recommendation.

Clinical and radiographic findings

The ulcer was hyperaemic but healing, and there was mild scoliosis, with a left lateral deviation of the tail at the level of the anal fin.

A biopsy taken from the tip of the right pectoral fin had no evidence of microscopic changes. A skin scrape taken from the ulcerative lesion contained a few unidentified non-pathogenic protozoal organisms and one free-living nematode. The fish was anaesthetised in 200 mg/litre of buffered tricane methanesulphonate (MS222) (Finquel; Argent Chemical Laboratories) for the purpose of radiographic examination (Love and Lewbart 1997) and maintained by delivering the anaesthetic-containing water through a syringe over its gills as needed. Dorsoventral radiographs revealed a right laterodorsal angulation involving the 14th, 15th and 16th trunk vertebrae (T14 to T16) at the level of the caudal swimbladder. The vertebrae at this site appeared to be osteopenic and the intervertebral spaces were not well delineated (Fig 1). Lateral views revealed a dorsolateral subluxation of the spinal column just caudal to the last rib, involving T14 and T15. The lateral angulation was considered to be due to a combination of a fracture and a subluxation. Several callused, mid-body fractures were apparent in the caudal ribs. The koi recovered uneventfully in fresh dechlorinated water; it resumed swimming with the group of fish and the ulcer started to heal; it was treated with trimethoprim-sulphadiazine for two more weeks, but no further treatment was considered necessary.

FIG 1: Collimated dorsoventral radiograph of the T14 to T16 region of koi 1. The spinal column deviates to the right and appears osteopenic, and the intervertebral spaces are poorly delineated

FIG 2: Collimated dorsoventral radiograph of koi 1, made immediately after the surgery. The scoliosis was not corrected but it was stabilised with five cortical bone screws, a k-wire, and polymethylmethacrylate bone cement

Six months later, the koi was reported to be swimming abnormally, and the scoliosis appeared to be more severe. The fish was anaesthetised as described above, and maintained on 100 mg/litre MS222 by using the Fish Anaesthesia Delivery System (Lewbart and Harms 1999). At the owner's request, chiropractic manipulations were performed on the fish by a licensed chiropractor. However, radiographs taken afterwards revealed that the scoliosis was unchanged.

Computed tomographic findings

One month later the fish was alert but unable to swim off the bottom of the pond. It had a marked scoliosis to the right with pronounced muscle atrophy of its right trunk. The fish was anaesthetised again and examined by computed tomography (CT) with 3 mm axial image slices (Bakal and others 1998) taken from the mid-body to the tail. The examination confirmed the radiographic findings and showed that the vertebral canal was stenotic or obliterated where the spine was affected. A three-dimensional computer program was used to reconstruct the CT findings. The scoliosis appeared to be progressive, and without vertebral stabilisation the spinal cord was likely to become further compressed. It was decided to treat the fish surgically, and a dead carp was obtained from a local market and used to determine the best surgical approach and method of stabilisation.

Surgical stabilisation

The following month the fish was induced in 200 mg/litre MS222 and maintained under general anaesthesia with 55 to 100 mg/litre MS222 by using the Fish Anaesthesia Delivery System. It was placed in sternal recumbency, the surgical site was wiped with a sterile cotton tip applicator, and scales over the incision site were removed with a number 10 scalpel blade and by plucking with forceps. A 3 cm incision was made into the epidermis a few millimetres to the right of the dorsal fin, at the level of vertebrae T11 to T16. The subcutaneous tissues and muscle were bluntly dissected with a number 15 scalpel blade, and reflected from the dorsal spinous process of the vertebral bodies with a periosteal elevator. The subluxation could not be reduced. When the affected vertebrae were visible, 2·0 mm cortical bone screws (Synthes) were placed into the right aspect of five vertebral bodies spanning the affected site, and polymethylmethacrylate (Surgical Simplex P radioopaque bone cement; Stryker Howmedica Osteonics) was applied in a strip spanning the screws; a 1·15 mm k-wire was then pressed into the hardening polymethylmethacrylate as reinforcement. The muscle layer was closed over the dorsal spinous process with 4-0 monofilament polyglyconate synthetic absorbable suture (Maxon; United States Surgical) in a simple interrupted pattern, and the skin was closed in a similar way.

Postoperative radiographs showed that the five screws, polymethylmethacrylate and wire had been placed at the site of the scoliosis. There was little cement around the most proximal screw, and there was still significant spinal deviation (Fig 2).

After surgery, the fish was reported to have recovered well. It was kept isolated from other fish in a small pool and fed enrofloxacin-impregnated paste food for two weeks. The skin sutures were removed 14 days after the surgery. Beginning one week after surgery, the fish was treated three times a week for 10 minutes by holding its tail, so that it attempted to swim away; after two weeks there was a noticeable increase in the fish's strength.

Two-and-a-half months after the surgery, the koi developed anorexia and lost weight. It was weak and weighed

only 749 g. It was tube-fed 10 ml of paste food and given 13·4 mg/kg thiamine hydrochloride (Vitamin B Complex Fortified; Phoenix Pharmaceutical) intramuscularly. Three months after the surgery it died, and was stored at 7°C until it was examined 24 hours later.

Pathological findings

The fish weighed 800 g, both its eyes were sunken and muscle atrophy resulted in markedly prominent vertebrae. The scoliosis involved T12 to T15 and bony changes were evident from T12 to T16, with T12 to T15 being moderately thickened and roughened bilaterally. The surgical implant was intact. Within the vertebral canal and cranial vault, the cerebrospinal fluid was slightly opaque and thickened; it contained degenerate granulocytes mixed with melanocytes, macrophages and erythrocytes in a slightly eosinophilic proteinaceous background matrix, consistent with inflammation. The posterior chamber of the swimbladder appeared mottled red on the tunica externa and contained approximately 2 ml of yellow, opaque, wispy proteinaceous fluid which was mildly cellular with no evidence of haemodilution; it contained a few granulocytes and fewer macrophages.

The vertebrae showed moderate signs of multifocal periosteal proliferation and perivertebral fibrosis, with moderate muscle atrophy around the affected site; fibrous tissue extended into and replaced the associated myofibres. There were scattered macrophages, haemosiderophages, a few granulocytes and mononuclear cells, and associated haemorrhage. Within the spinal cord, evidence of chronic, diffuse, mild meningitis was provided by the expansion of the meninges by macrophages, extravasated erythrocytes, and a few granulocytes and lymphocytes. Evidence of spongiosis and neuronal necrosis was provided by the multifocal swelling of myelin sheaths, and neurons that were swollen and lightly basophilic. The swimbladder showed signs of chronic, moderate, diffuse lymphoplasmacytic and histiocytic pneumocystitis and serositis, and it was moderately oedematous. Diffuse superficial adherent bacteria were also observed. The gills showed signs of moderate, multifocal, diffuse granulocytic branchitis, and a moderate number of metazoans were identified as monogeneic trematodes. The fish had chronic, mild lymphoplasmacytic enteritis. At the surgical site, the skin had chronic, moderate, focally extensive lymphoplasmacytic dermatitis and myositis with moderate myofibre atrophy and mild, multifocal epithelial hyperplasia.

CASE HISTORY 2

In August 2002, a one-year-old, 37 cm, 730 g, female gin rin kohaku koi from the same pond, but acquired from a different breeder, developed scoliosis. The owner reported that two months earlier a tree near the pond had been struck by lightning and that several days later the koi was found struggling to swim, with an acute curvature to its back. At first the fish appeared to be recovering, but later it had difficulty in swimming and was not eating well.

Clinical and radiographic findings

The koi was bright, alert and in good body condition, apart from mild muscle atrophy at the level of the left mid-body, dorsal to the anal fin. It was anaesthetised with 200 mg/litre MS222 to enable phlebotomy and radiographic examination. Its packed-cell volume and total protein concentration were within their normal ranges (Groff and Zinkl 1999), and a gill biopsy was apparently normal. Radiographs revealed a T15 vertebral body compression fracture and a narrowing of the T15 to T16 intervertebral space. The spine and the caudal swimbladder curved to the right, beginning at the cranial end of the caudal swimbladder.

Computed tomographic findings

Slices of 3 mm through the spine were acquired by CT and confirmed the malalignment by showing that there was a slight leftward shift of the entire vertebral column in the mid-spine region as a result of vertebral subluxation, accompanied by a mild rightward tilt of the dorsal processes.

Surgical stabilisation

One week later the koi weighed 703 g (a 4 per cent decrease). The surgical approach was made left of the dorsal fin and the vertebrae were stabilised by the same technique as for koi 1, except that six 2·0 mm cortical bone screws were used instead of five. The fish was given 10 mg/kg enrofloxacin as a perioperative antibiotic intramuscularly just caudal to the dorsal fin, and 0·4 mg/kg butorphanol tartrate (Torbugesic 3 mg; Fort Dodge) in the same way to provide analgesia. Postoperative radiographs showed that the six screws and the accompanying bone cement had been placed along the dorsal aspect of the 13th to the 18th vertebral bodies. Gas consistent with the surgery was present in the dorsal tissues.

After the surgery the fish did well; it was kept isolated from other fish in a horse trough containing approximately 750 litres of water containing 1 g/litre of salt; it was fed trout chow and enrofloxacin-impregnated paste food for two weeks, and 50 per cent of the water was changed every one to three days. From the day after surgery the fish was encouraged to swim daily for five to 10 minutes by swirling a metal rod behind it. Ten days after the surgery, the fish weighed 726 g, but two of the simple interrupted sutures near the centre of the incision had pulled through the skin, leaving an approximately 3 cm gap through which the surgical implant was visible. The skin appeared to be pulling away from the suture material two sutures caudal to the dehisced sutures. These sutures were removed and a culture was taken from near the surgical site; heavy growths of *Escherichia coli* and *Aeromonas hydrophila* were obtained, both of which were resistant to enrofloxacin but sensitive to gentamicin. A caseous ribbon of cream-coloured purulent material was entwined in a few of the muscle layer sutures. This material was removed and the wound was flushed with 1 litre of lactated Ringer's solution (LRS) (Baxter Healthcare Corporation). Before the wound was closed, 1·8 mg amikacin sulphate (Amiglyde-V 50 mg/ml; Fort Dodge), diluted to half strength with LRS, was placed inside the surgical cavity, and the skin was closed with a horizontal mattress pattern, using 3-0 Maxon on a cutting needle. The fish was given 5 mg/kg amikacin sulphate intramuscularly every 48 hours for 14 days. This aminoglycoside was chosen in preference to gentamicin because it is less nephrotoxic and if the organisms were sensitive to gentamicin they were also likely to be sensitive to amikacin. Two weeks later the sutures were removed and gill, skin and fin biopsies were taken. The fish weighed 698 g, having lost 30 g since its last visit, and cooked shrimp (14 g protein/day) was added to its diet. The incision site had healed well. *Ichthyobodo* species was found on the gill and skin biopsies and the animal was treated with a formalin dip, containing 6 ml of 37 per cent formaldehyde per 37·85 litres of water, for 10 minutes.

Over the next month, the koi's appetite decreased, its weight decreased to 684 g and it was still positive for the *Ichthyobodo* organism. In addition, *Dactylogyrus* species was found on skin and fin biopsies. The koi was treated twice, 48 hours apart, for 10 minutes with a formalin dip containing 8 ml of 37 per cent formaldehyde per 37·85 litres of water, and by the owner with 1 ml/378·5 litres of 50 mg/ml closantel and 75 mg/ml mebendazole (Supaverm; Janssen Animal Health). After this treatment, only one *Ichthyobodo* species was found on a skin scrape, and no further treatment was given. The koi continued to lose weight and seven days later

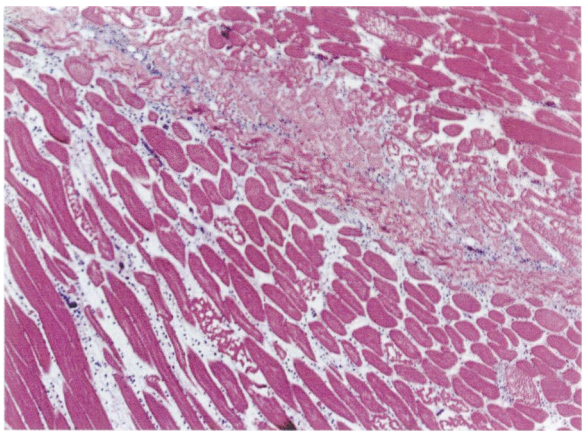

FIG 3: Inflammatory cells forming tracks among necrotic myofibres in the muscles of the right trunk of koi 2. Haematoxylin and eosin. x **400**

it weighed 659 g. Two months after the surgery the owner noticed an approximately 4 cm^2 swollen area on the fish's right peduncle and administered a 10 mg/kg intramuscular dose of enrofloxacin, following the veterinarian's advice. The fish died the following day and was stored at 7°C until it was examined 24 hours later.

Pathological findings

The fish weighed 696 g and had a 5·5 x 6·5 x 2 cm fluctuant swelling over its right caudal abdomen, extending halfway down the tail, which contained approximately 7 ml of pale yellow opaque fluid with red streaks; the surrounding muscle was discoloured and necrotic. An aerobic culture of the fluid yielded *Aeromonas hydrophila*, which was sensitive to ciprofloxacin and gentamicin.

The surgical implant was intact, but there was a small fistulous tract starting at the base of the most caudal skin suture and extending dorsally through the skin. The posterior swimbladder contained 0·5 ml of dark tan mucinous material which contained mucus cells, white blood cells and numerous bacteria in a homogeneous globular eosinophilic background matrix, consistent with inflammation. The skin and the gills were covered in excess mucus.

The muscle surrounding the abscess contained large numbers of macrophages and large lymphocytes tracking between and among regions of necrotic myofibres (Fig 3). There was granulation tissue at the edges of some muscles. The sections of the spine and skeletal muscle at the surgical site showed signs of spinal cord demyelination, and spinal root mononuclear inflammation, degeneration and necrosis. At the same site there was bone necrosis and remodelling with granulation of the surrounding tissue. Within the swimbladder, the epithelial layer was absent, and the subepithelium was oedematous and infiltrated with new vessels, macrophages, lymphocytes and polymorphonuclear cells. The adipose tissue, heart, brain and spinal cord also contained a mononuclear infiltrate. The gills had severe, diffuse heterohistiocytic branchitis and there were trematodes within the lesions. The cortical portion of one tail kidney contained multiple ectatic tubules, with attenuated epithelium, that were filled with amorphous, brightly eosinophilic material. The spleen was diffusely necrotic.

DISCUSSION

In domestic mammals, scoliosis is most commonly a congenital defect. In dogs and horses it is usually the result of a congenital malformation of the vertebrae (Colter 1993), but environmental teratogens have been implicated in cows (Leipold and others 1974). Scoliosis has been observed in fish of all ages. Congenital defects have occurred in fingerlings and fry. Organophosphates, vitamin C deficiency and tryptophan deficiency may affect all age groups, and in these circumstances most of the fish in a pond are usually affected, whereas a spasmodically faulty submersible pump or a lightning strike may affect only one or a few fish in a pond. Trauma to the musculoskeletal system due, for example, to an intramuscular injection, rough handling, sudden bursts of speed and pond hazards may affect a single fish which often goes unnoticed until it is observed swimming abnormally.

In domestic mammals, the surgical correction of scoliosis is not usually practicable because the muscular and skeletal changes associated with the disease are severe, and the correction of the initial defect typically does not correct the deformity. The scoliosis in these two koi was attributable to compression fractures, and in the rare cases when scoliosis is attributable to vertebral fractures in domestic mammals, they can be stabilised by a variety of methods, including external skeletal fixation, spinal stapling, dorsal spine plating, vertebral body plating, pins and cement, or a combination of these methods (Seim 2002).

Internal fixation was chosen for both koi because a correction of the deformity could not be hoped for and the surgery was aimed at vertebral decompression and stabilisation. In fish, internal fixation has several benefits over external fixation. First, it uses less hardware and therefore has less effect on the fish's buoyancy. Although closed-cell foam can be added to improve balance and flotation (Lewbart 1998), it increases the drag on a fish as it swims, and has the potential to exhaust an already compromised animal. Secondly, internal fixation allows the vertebrae to be stabilised with little disruption to the spinal column, whereas external fixation would require the vertebral column to be broken to allow for realignment. Pin tracts from external fixators have the potential to wick bacteria that may cause an infection, and very clean water would be needed in the fish's recovery pool to decrease this risk. The size of the fish's vertebrae was also taken into consideration: appropriate screws could be obtained to make the stabilisation rigid with only the affected and nearby vertebrae being involved; extending the stabilisation too far down the spine might have affected the fish's ability to swim.

In both cases the site of the lesion was consistent with that commonly reported in trauma-related vertebral fractures in koi (Barlow 1993), cats (Thatcher 1993) and dogs (Hoerlein 1978). In the koi, the lesions were between T14 and T16, T14 being the last trunk vertebra to have ribs attached. Spinal fractures and luxations most commonly occur at the junctions between moveable and stable spinal segments. The ribs have a stabilising effect and, compared with the rest of the spine, the spine caudal to the ribs has the greatest range of motion in flexion and extension. As a result, the vertebrae in this region are subject to forces and loads that do not affect the other vertebrae.

Although its death was not necessarily attributable to the surgery, the first fish survived only three months and, despite more intense aftercare, the second fish survived less than two months. Postmortem examinations revealed multiorgan inflammation, including meningitis, pneumocystitis, branchitis, enteritis, dermatitis, myositis, myelitis, myocarditis and steatitis that could not be definitively linked to the surgical implants, but was suggestive of sepsis. Both the fish lost weight, became parasitised and suffered bacterial infections.

By the time the first koi underwent surgery it had had noticeable scoliosis for nine months, with appreciable muscle atrophy, severe skeletal changes and difficulty in swimming. The angulation of the spinal cord was so acute that it

was under considerable pressure. Decompression was avoided because it could have resulted in the spinal cord being displaced outside the vertebral canal.

The second koi was a better candidate for the procedure because its scoliosis was less severe and it underwent surgery only two months after it was thought to have been injured. However, its smaller size made it difficult to lift the muscle cleanly from the dorsal spinous processes of the vertebral bodies, and muscle atrophy had already developed; intensive management and supportive care did not prevent it from deteriorating.

The use of antibiotic-impregnated polymethylmethacrylate or hydroxyapatite cement (Ethell and others 2000) in place of the plain polymethylmethacrylate placed over the screws might have been beneficial because, according to in vitro studies, polymethylmethacrylate may compromise local immunity (Shirtliff and others 2002); local, sustained concentrations of antimicrobial agents in the compromised area might have helped. However, the wounds of three of 18 dogs treated with gentamicin-impregnated polymethylmethacrylate during vertebral stabilisation still became infected (Blass and Seim 1984). Keeping the fish on oral or injectable antibiotics for a longer period might also have improved the outcome. It was observed that horizontal mattress sutures provided more tension relief than simple interrupted sutures, and their use from the beginning might have prevented the second koi's initial infection.

Spinal vertebral stabilisation offers a possible therapeutic treatment for scoliosis due to vertebral fracture in fish. Although the technique and postoperative management require refinement, these cases provide information that should guide and benefit future implant surgeries in fish.

ACKNOWLEDGEMENTS

The authors thank Nancy Love, Lenore Mohammadian and Sandy Wang for their radiological assistance and interpretations, Talmage Brown for his pathology assistance and interpretations, Craig Harms for a review of the manuscript, Christian Osmond for photographic documentation and Shane Christian for assistance with case management and animal husbandry.

References

ALAM, M. K. & MAUGHAN, O. E. (1993) Acute toxicity of selected organophosphorus pesticides to *Cyprinus carpio* and *Barilius vagra*. *Journal of Environmental Science and Health. Part B: Pesticides, Food Contaminants, and Agricultural Wastes* **28,** 81-89

BAKAL, R. S., LOVE, N. E., LEWBART, G. A. & BERRY, C. R. (1998) Imaging a spinal fracture in a kohaku koi (*Cyprinus carpio*): techniques and case history report. *Veterinary Radiology and Ultrasound* **39,** 318-321

BARLOW, A. M. (1993) 'Broken backs' in koi carp (*Cyprinus carpio*) following lightning strike. *Veterinary Record* **133,** 503

BLASS, C. E. & SEIM, H. B. (1984) Spinal fixation in dogs using Steinman pins and methylmethacrylate. *Veterinary Surgery* **13,** 203-210

COLTER, S. B. (1993) Congenital anomalies of the spine. In Disease Mechanisms in Small Animal Surgery. Philadelphia, Lea & Febiger. pp 950-959

COUCH, J. A., WINSTEAD, J. T. & GOODMAN, L. R. (1977) Kepone-induced scoliosis and its histological consequences in fish. *Science* **197,** 585-587

ETHELL, M. T., BENNETT, R. A., BROWN, M. P., MERRIT, K., DAVIDSON, J. S., & TRAN, T. (2000) In vitro elution of gentamicin, amikacin, and ceftiofur from polymethylmethacrylate and hydroxyapatite cement. *Veterinary Surgery* **29,** 375-382

GROFF, J. M. & ZINKL, J. G. (1999) Haematology and clinical chemistry of cyprinid fish: common carp and goldfish. *Veterinary Clinics of North America: Exotic Animal Practice* **2.3,** 741-776

HALVER, J. E. & HARDY, R. W. (1994) L-ascorbyl-2-sulfate alleviates Atlantic salmon scurvy. *Proceedings of the Society for Experimental Biology and Medicine* **206,** 421-424

HALVER, J. E. & SHANKS, W. E. (1960) Nutrition of salmonid fishes. Indispensable amino acids for sockeye salmon. *Journal of Nutrition* **72,** 340-346

HOERLEIN, B. F. (1978) Spinal fractures, luxations, and fusion. In Canine Neurology: Diagnosis and Treatment. 3rd edn. Philadelphia, W. B. Saunders. pp 561-594

JOHN, T. M., GEORGE, J. C., HILTON, J. W. & SLINGER, S. J. (1979) Influence of dietary ascorbic acid on plasma lipid levels in the rainbow trout. *International Journal for Vitamin and Nutrition Research* **49,** 400-405

JOHNSON, E. L. (1997) Koi Health and Disease: Beginner to Advanced Life-Saving Technology. Athens, Reade Printers. pp 20, 25, 87

KLOPPEL, T. M. & POST, G. (1975) Histological alteration in tryptophan-deficient rainbow trout. *Journal of Nutrition* **105,** 861-866

LEIPOLD, H. J., HUSTON, K. & HULBERT, L. C. (1974) Congenital syndrome in Hereford calves with kyphoscoliosis, arthrogryposis, and palatoshisis. *Cornell Veterinarian* **64,** 123

LEWBART, G. A. (1998) Self-assessment Color Review of Ornamental Fish. Ames, Iowa State University Press. pp 111-112

LEWBART, G. A. & HARMS, C. (1999) Building a Fish Anesthesia Delivery System. *Exotic DVM* **1.2,** 25-28

LOVE, N. E. & LEWBART, G. A. (1997) Pet fish radiography: technique and case history reports. *Veterinary Radiology and Ultrasound* **38,** 24-29

NOGA, E. J. (1996) Fish Disease Diagnosis and Treatment. St Louis, Mosby. pp 126-127, 221-224

POST, G. W. (1993) Nutrition and nutritional diseases of Salmonids. In Fish Medicine. Philadelphia, W. B. Saunders. pp 343-358

POSTON, H. A. & RUMSEY, G. L. (1983) Factors affecting dietary requirements and deficiency signs of L-tryptophan in rainbow trout. *Journal of Nutrition* **113,** 2568-2577

SEIM, H. B., III (2002) Surgery of the thoracolumbar spine. In Small Animal Surgery. 2nd edn. Philadelphia, Mosby. pp 1269-1301

SHARBER, N. G. & CAROTHERS, S. W. (1988) Influence of electrofishing pulse shape on spinal injuries in adult rainbow trout. *American Journal of Fisheries Management* **8,** 117-122

SHIRTLIFF, M. E., CALHOUN, J. H. & MADER, J. T. (2002) Experimental osteomyelitis treatment with antibiotic-impregnated hydroxyapatite. *Clinical Orthopaedics* **401,** 239-247

THATCHER, C. (1993) Biomechanics of cranial fractures, spinal fractures, and luxations. In Disease Mechanisms in Small Animal Surgery. Philadelphia, Lea & Febiger. pp 1006-1008

WADDINGTON, P. (1995) Caring. In Koi Kichi. Liverpool, Kingprint. pp 156-192

WALTON, M. J., COLOSCO, R. M., COWEY, C. B., ADRON, J. W. & KNOX, D. (1984) The effects of dietary tryptophan levels on growth and metabolism of rainbow trout (*Salmo gairdneri*). *British Journal of Nutrition* **51,** 279-287